

A Smile Transformation with Lumineers™ by Cerinate®

Peter D. Vastardis, DMD, PC



Imagine if plastic surgeons could transform a patient's facial and physical features without the need for anesthesia, where trauma would be non-existent and where swelling, bruising and pain would never be an issue. If this were possible, plastic surgical practices would be overflowing with patients in addition to their incredible growth rate over the last few years.

According to the *American Society for Aesthetic Plastic Surgery*, 8.7 million people had cosmetic surgery in 2003, up 33% from the previous year¹. The top elective procedures included those which involved facial esthetics such as chemical peels, microdermabrasion, botox injections and eyelid surgery². We have all at one time or another had the chance to watch one of the many popular makeover television shows such as *Extreme Makeover* and *The Swan*, where patients are chosen to have extreme facial and dental transformations. Viewers observe the post-op pain, swelling, bruising that patients must go through in order to attain the desired results. The immediate consequences appear to be right out of a 1950's horror movie. Yes, we know the outcomes are usually wonderful with proper healing, which often takes months, but patients seem to still go ahead and seek these extreme surgical procedures.

Driven by Cerinate Porcelain's non-invasive Lumineers, modern esthetic dentistry is now making these extreme treatment modalities obsolete. The "never again" comments often made by plastic surgical patients are never heard from Lumineers patients because the procedures are pain-free. Veneers enable dentists to re-design smiles in just two visits, thus giving patients the unique opportunity to attain complete, life-changing dental makeovers without removing any painful tooth structure.


The following illustrates one such case where a patient was given a life changing esthetic dental makeover with the Lumineers by Cerinate porcelain system.

Cerinate porcelain is a feldspathic porcelain that can be finished to a thickness

of 0.2 mm. Its flexural strength is similar to the aluminum oxide reinforced porcelain cores. It has a low coefficient of thermal expansion, which allows for a decreased rate of fracture and de-bonding³.

Val had been a patient in our practice for several years. His family was never informed nor given the option to have his teeth orthodontically corrected as a youngster. When they arrived to the U.S. from his native Italy, finances also became an issue for his family. Over the years, Val's desire to change his smile increased. His main concern was the removal of sound, healthy tooth structure. He refused to have orthodontic treatment, which I always feel is the first option. I described a system that existed where I could give him the desired results with minimal tooth reduction, which increased his interest in this treatment.

We had Val visit us at a separate appointment to take the standard 12 AACD digital images⁴, study models; face-bow transfer, stick bite and CR bite registration. Gathering and documenting this baseline information is a must to attain successful results. Preparation of any case must be performed to avoid unnecessary complications for both the patient and restorative dentist. Comprehensive dental examination, including digital radiographs, caries, TM joint and periodontal assessments were normal. His dental home care was good and he always presented for his re-care appointments. As can be seen in **Fig. 1**, Val always wished that the "spaces" between his teeth could be closed, his midline shifted, and that he could have a slightly brighter, more youthful smile. He also felt that the linguo-version of tooth #7 gave his smile the appearance of a missing tooth.



Continued on page 72

Figure 2 shows an unretracted view of the patient's teeth. Close-up 1:2 retracted views showed the multiple diastemas and cross bite evident with tooth #7 and the distal of # 10 as well as the anterior overbite (Figs. 3, 4 and 5).

A close-up view of the patient's anterior teeth using a contrastor showed disproportionate length of his central incisors, which exacerbated the central dominance and golden proportion theorems (Fig. 6a, b, c). The most critical aspects of proper smile design are the creation of balance by correctly placing the midline of the two central incisors within the frame of the face, perpendicular to the horizon followed by establishing favorable proportions with the lengths and widths of the anterior teeth⁵.

Study models were taken and sent to the Cerinate Smile Design Studios in Santa Maria, CA, to discuss treatment options for the patient. As is the standard in my practice, diagnostic waxups are a must to help serve as a *dental blueprint* and also allow me to show the patient what I can do for them esthetically (Fig. 7). I also use the waxup to fabricate a putty matrix using Ivoclar's Sil-Tech putty to preview the case intraorally so I can see where problems may arise and also to see if the esthetic outcome meets or exceeds the patient's expectations (Fig. 8). Dr. Galip Gurel, author of *"The Science and Art of Porcelain Laminates"* calls these phases, *"Aesthetic Pre Recontouring or APR phase"* and the temporary phase *"Aesthetic Pre-evaluative Temporaries or APT phase."*

It was determined that the case would require some tooth reduction in order for the case to be successful. The models were returned with the areas marked in stone that would require slight reduction and areas where slight enameloplasty on the opposing arch would remove any eccentric contacts that would alter the patient's occlusion and/or fracture the final porcelain restorations (Figs. 9a, b, and Fig.10).

By having the patient preview the case intraorally, changes can be made. It also immediately gets the patient excited about the procedure. Often times, the patient cannot fully understand how the

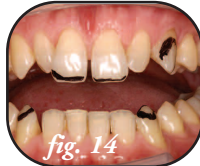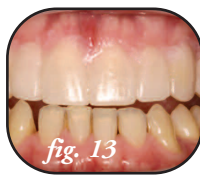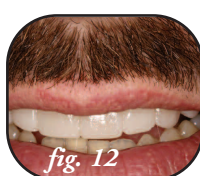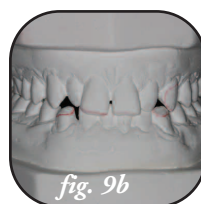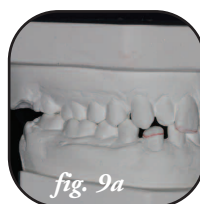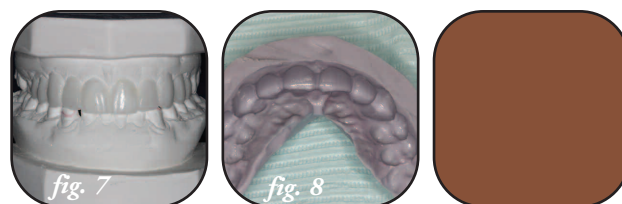
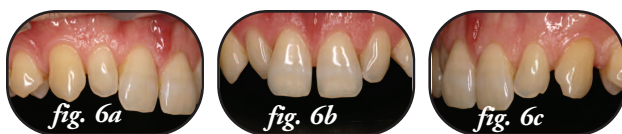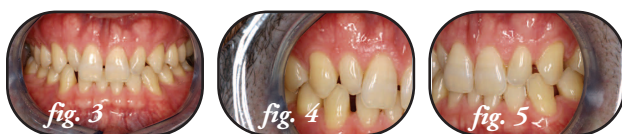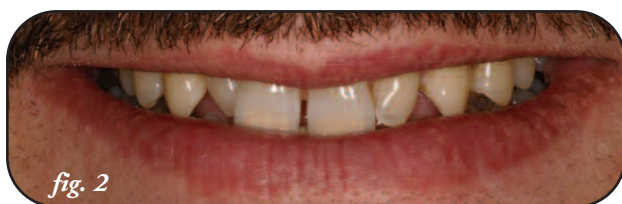
diagnostic wax-up will look on their teeth, much like one cannot understand what a certain outfit will look like without first trying it on. We *"dress the teeth"* for the patient in our office. The patient's expectations are determined prior to any treatment. Educating them about any unforeseen problems that may arise will surely help alleviate any misunderstandings.

We begin by simply marking the midline of the patients two central incisors on the putty matrix as a guide for placement, inject a syringable bis-acryl temporary material such as Luxatemp by DMG/Zenith within the matrix and seat onto the teeth. Once set, the putty matrix is removed which usually allows the temporary to lock onto the unprepared teeth. The excess flash on the buccal gingival margins can or does not necessarily have to be removed. I adjust the occlusion at this time. Both the patient and I want to simply *"preview"* how the proposed dimensions of the teeth appear within the full facial frame. If the patient and I feel changes should be made, they are performed at this time. I also evaluate the patient's phonetics by having them confirm "F" and "V" sounds for proper incisal length as well as "S" sounds to determine if the tooth-to-tooth relationship is satisfactory. I do not worry about "T" and "D" sounds because I have not removed any of the lingual enamel. When the patient and I feel that they are comfortable, an alginate impression is taken of the *approved temporaries* and an *approved provisional model* is poured and sent to the lab. Digital photographs of the temporaries are also taken of the patient's full face in repose and smiling views (Figs. 11, 12 and 13). These digitized images offer the ceramist visual communication and also supplement the written analysis I have provided.

Once the patient accepts the overall treatment, the patient is appointed to begin the case.

The area where slight enamel removal is required is transferred to the patient's natural enamel using a black marker such as an ultra-fine point Sharpie (Fig. 14).

Continued on page 74



Den-Mat Guest Editorial

Continued from page 72

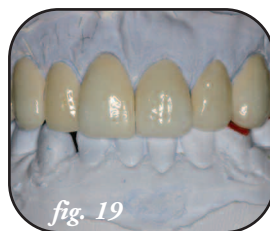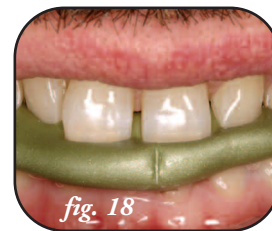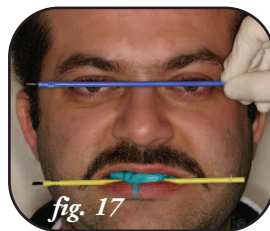
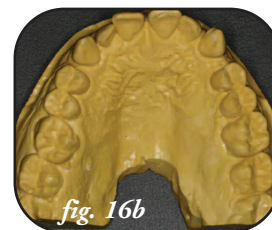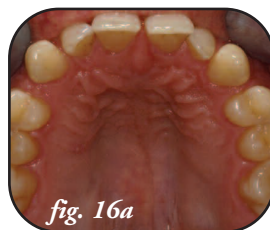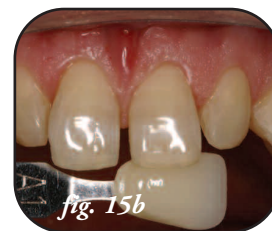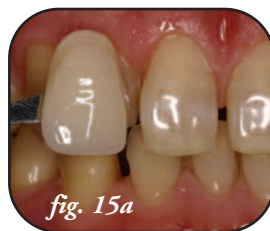In this case, as with most cases using the Cerinate porcelain system, no anesthesia was administered. The patient did not want super white teeth, so bleaching was not performed. However, a lighter shade selection of porcelain was chosen to slightly brighten the patients existing teeth (*Figs. 15a, b*). Mandibular arch bleaching using the Rembrandt system would be performed at a later time.

It was determined that it was best to have ten Cerinate Lumineers fabricated to close the multiple diastemas, establish balance and proportion and to widen the patient's smile. Occlusal views of the pre-treatment case also show the large spaces that existed distal to his canines (*Figs. 16a and b*).

A facebow transfer, stick bite with corrected midline location (*Figs. 17 and 18*), final shade determination with color mapping⁶, and surface texture desired was all incorporated within the prescription. While shade matching is important, properties such as translucency, surface roughness, fluorescence, opalescence and gloss must be conveyed to the ceramist⁷. I also burned a CD-ROM of all the digital photographs taken to help the Studio view the case on their own computer monitor.

The completed case returned and was tried in using Ultra-Bond[®] Plus Try-In Paste (*Figs. 19 and 20*).

Continued on page 76

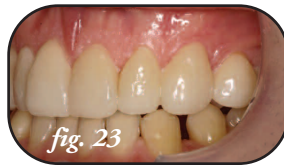
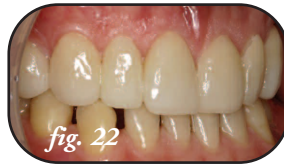
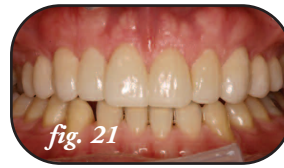Den-Mat Guest Editorial

Continued from page 74

Once the patient previewed his new smile (Figs. 21, 22, 23), the case was bonded using the Tenure® and Ultra-Bond systems. Occlusion was checked to verify for any discrepancies in porcelain. Since only minor tooth preparation was required, all adjustments were in porcelain and only minor adjustments were made on the opposing arch due to the patient's crossbite on teeth #7 and 10. Anterior and lateral guidance was verified so that no interferences were present and that immediate disclusion of all posterior teeth was present⁸. After final finishing was performed, polishing was achieved using the Dialite porcelain polishers by Brasseler and Porcelize diamond polish by Cosmedent. As with all my esthetic cases, a soft night guard was fabricated to protect the restorations from any nocturnal habits the patient may have.

The patient's final dental esthetic makeover can be seen in his smile from his original full facial digital photographs to the final result. The widening of the smile and the reduction of negative buccal corridor space are evident which allowed for a more natural, youthful and proportionate smile, all with minimal healthy enamel ever being altered (Figs. 24 and 25).



Dr. Vastardis maintains an active general dental practice with an emphasis on restorative, esthetic and implant dentistry in Garden City, New York. Dr. Vastardis graduated from Tufts University School of Dental Medicine. He is the founder of www.Floss.com, one of the most respected consumer educational dental websites on the internet today. He is a member of the American Dental Association, American Academy of Cosmetic Dentistry, Nassau County Dental Society, Academy of Osseointegration and The International Academy for Sports Dentistry. Dr. Vastardis has lectured at the national level on topics of esthetic and restorative dentistry. He can be reached by calling (516) 326-0770 or by email: peter@GardenCityDentistry.com.

1. Report of the 2003 procedural statistics: National Clearinghouse of Plastic Surgery Statistics. Arlington Heights, IL: American Society of Plastic Surgeons, 2004.
2. American Society for Aesthetic Plastic Surgery: Top Surgical Cosmetic Procedures, <http://www.surgery.org/press/statistics-2003.php>

3. Shuman, IE., Aesthetic Correction of a Damaged Occlusion Using Varied Preparation Designs and Pressed Ceramic Restorations, Dentistry Today, March 2004 66-75.
4. American Academy of Cosmetic Dentistry: A Guide to Accreditation Photography- Photographic Documentation and Evaluation in Cosmetic Dentistry.

5. Rufenacht CR. Fundamentals of Esthetics. Chicago, IL, 1990, Quintessence Pub Co. 6. Vanini L, Mangani FM: Determination and Communication of Color Using the Five Color Dimensions of Teeth, Pract Proced Aesthet Dent 13:19, 2001.
7. Paravina, RD, Powers,JP: Esthetic Color Training in Dentistry, St.Louis, MO, 2004 Elsevier Mosby Pub Co.
8. Dawson P. Evaluation, Diagnosis and Treatment of Occlusal Problems (2nd Ed.). St. Louis, MO, 1989, Mosby